

|  |  |
|--|--|
| <ul style="list-style-type: none"><li>Electronic copy is controlled under document control procedure. Hard copy is uncontrolled &amp; under responsibility of beholder.</li><li>It is allowed ONLY to access and keep this document with who issued, who is responsible and to whom it is applicable.</li><li>Information security code: <input checked="" type="checkbox"/> Open <input type="checkbox"/> Shared -Confidential<br/><input type="checkbox"/> Shared-Sensitive <input type="checkbox"/> Shared-Secret</li></ul> | <ul style="list-style-type: none"><li>النسخة الإلكترونية هي النسخة المضبوطة وفق إجراء ضبط الوثائق. النسخ الورقية غير مضبوطة وتقع على مسؤولية حاملها.</li><li>يسمح بالوصول وباحتفاظ بهذه الوثيقة مع مصدرها أو مع المسؤول عن تطبيقها أو مع المطبق عليهم.</li><li>تصنيف امن المعلومات: <input checked="" type="checkbox"/> بيانات مفتوحة <input type="checkbox"/> مشارك -خاص<br/><input type="checkbox"/> مشارك -حساس <input type="checkbox"/> مشارك -سري</li></ul> |
|--|--|

# DHA TELEHEALTH CLINICAL GUIDELINES

## FOR VIRTUAL MANAGEMENT OF ALLERGIC

### CONTACT DERMATITIS – 36

Version 1

Issue date: 27/07/2021

Effective date: 27/07/2021

Health Policies and Standards Department

Health Regulation Sector (2021)

## INTRODUCTION

Dubai Health Authority (DHA) is the responsible entity for regulating, licensing and monitoring health facilities and healthcare professionals in the Emirate of Dubai. The Health Regulation Sector (HRS) is an integral part of DHA and was founded to fulfil the following overarching strategic objectives:

Objective #1: Regulate the Health Sector and assure appropriate controls are in place for safe, effective and high-quality care.

Objective #2: Position Dubai as a global medical destination by introducing a value-based, comprehensive, integrated and high-quality service delivery system.

Objective #3: Direct resources to ensure happy, healthy and safe environment for Dubai population.

## ACKNOWLEDGMENT

This document was developed for the Virtual Management of Allergic Contact Dermatitis in collaboration with Subject Matter Experts. The Health Policy and Standards Department would like to acknowledge and thank these professionals for their dedication toward improving the quality and safety of healthcare services.

### The Health Regulation Sector

### Dubai Health Authority

## TABLE OF CONTENTS

|  |           |
|--|-----------|
| <b>EXECUTIVE SUMMARY</b>               | <b>4</b>  |
| <b>DEFINITIONS/ABBREVIATIONS</b>       | <b>6</b>  |
| <b>1. BACKGROUND</b>                   | <b>7</b>  |
| <b>2. SCOPE</b>                        | <b>8</b>  |
| <b>3. PURPOSE</b>                      | <b>8</b>  |
| <b>4. APPLICABILITY</b>                | <b>8</b>  |
| <b>5. RECOMMENDATION</b>               | <b>8</b>  |
| <b>6. SYMPTOMS</b>                     | <b>11</b> |
| <b>7. RED FLAGS</b>                    | <b>11</b> |
| <b>8. DISEASE COURSE</b>               | <b>12</b> |
| <b>9. DIAGNOSIS</b>                    | <b>13</b> |
| <b>10. DIFFERENTIAL DIAGNOSIS</b>      | <b>17</b> |
| <b>11. MANAGEMENT</b>                  | <b>17</b> |
| <b>12. SUMMARY AND RECOMMENDATIONS</b> | <b>24</b> |
| <b>13. REFERRAL CRITERIA</b>           | <b>26</b> |
| <b>REFERENCES</b>                      | <b>28</b> |

## EXECUTIVE SUMMARY

Telehealth is based on Evidence Based Practice (EBP) which is the conscientious, explicit and judicious use of current best evidence in making decisions about the care of the individual patient.

It means integrating individual clinical expertise with the best available external clinical evidence and guidelines from systematic research.

EBP is important because it aims to provide the most effective care virtually, with the aim of improving patient outcomes. As health professionals, part of providing a professional service is ensuring that practice is informed by the best available evidence.

This guideline is presented in the format comprising of clinical history/symptoms, differential diagnosis, investigations and management. Identification of 'Red Flags' or serious conditions associated with the disease is an essential part of this telehealth guideline as it aids the physician to manage patients safely and appropriately by referrals, if indicated during virtual telehealth assessment, to ER, family physicians or specialists for a face to face management.

Allergic contact dermatitis is the classic presentation of a T cell-mediated, delayed-type hypersensitivity response to exogenous agents.

The words "dermatitis" and "eczema" are often used interchangeably to describe a pattern of inflammation of the skin characterized by erythema, vesiculation, and pruritus.

Chronic exposure typically leads to moderation of the erythema accompanied by lichenification and persistence of itch. The clinical presentation may vary depending upon the triggering agent

and individual's reactivity, but, in most cases, the lesions are primarily confined to the site of contact.

## DEFINITIONS/ABBREVIATIONS

**Virtual Clinical Assessment:** Is the evaluation of the patient's medical condition virtually via telephone or video call consultations, which may include one or more of the following: patient medical history, physical examination and diagnostic investigations.

**Patient:** The person who receives the healthcare services or the medical investigation or treatment provided by a DHA licensed healthcare professional.

## ABBREVIATIONS

|               |   |   |
|---------------|---|---|
| <b>ACD</b>    | : | Allergic Contact Dermatitis                           |
| <b>DHA</b>    | : | Dubai Health Authority                                |
| <b>EBP</b>    | : | Evidence Based Practice                               |
| <b>EDTA</b>   | : | Disodium Ethylenediamine Tetra-Acetate                |
| <b>ER</b>     | : | Emergency Room  |
| <b>HRS</b>    | : | Health Regulation Sector                              |
| <b>ICD</b>    | : | Irritant Contact Dermatitis                           |
| <b>KOH</b>    | : | Potassium Hydroxide                                   |
| <b>MCI/MI</b> | : | Methylchloroisothiazolinone and Methylisothiazolinone |
| <b>MI</b>     | : | Methylisothiazolinone                                 |
| <b>NSAIDs</b> | : | Nonsteroidal Anti-Inflammatory Drugs                  |

## 1. BACKGROUND

### 1.1. Epidemiology and Risk Factors

The incidence and prevalence of Allergic Contact Dermatitis (ACD) in the general population are not known. Data are often extrapolated from surveillance studies on occupational dermatitis. The agents most frequently implicated included latex materials, protective equipment, soap and cleansers, resins, and acrylics. Information on the main allergens responsible for contact dermatitis in the general population is derived from retrospective studies of patch testing referral centers. Risk factors for ACD include:

- 1.1.1. Occupation – Workers at highest risk include health professionals, chemical industry workers, beauticians and hairdressers, machinists, and construction workers.
- 1.1.2. Age – ACD was once considered a disorder of the adult population. Children were thought to be spared because of a low exposure to potential allergens and an immature immune system. However, it is now recognized that contact sensitization begins in early childhood via exposures such as vaccinations, piercing, topical medications, and cosmetics.
- 1.1.3. The incidence of ACD increases with age. Repetitive and prolonged exposure to potential sensitizers may account for the high rate of ACD

in older adults. Medical comorbidities, including stasis dermatitis and venous ulcerations, are contributing factors.

- 1.1.4. History of atopic dermatitis – The role of atopy in ACD is controversial, although several studies report a high rate of positive patch tests among atopic individuals.

## **2. SCOPE**

- 2.1. Telehealth services in DHA licensed Health Facilities.

## **3. PURPOSE**

- 3.1. To support the implementation of Telehealth services for patients with complaints of Allergic Contact Dermatitis in Dubai Health Authority (DHA) licensed Health Facilities

## **4. APPLICABILITY**

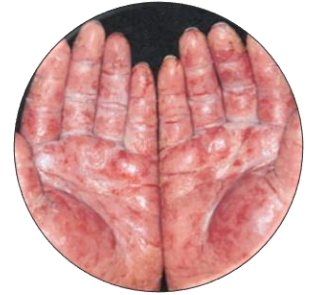- 4.1. DHA licensed physicians and health facilities providing Telehealth services.
- 4.2. Exclusion for Telehealth services are as follows
- 4.2.1. Emergency cases where immediate intervention or referral is required.
- 4.2.2. Prescribe Narcotics, Controlled or Semi-Controlled medications.

## **5. RECOMMENDATION**

- 5.1. Virtual Clinical Assessment: Clinical History/Symptoms
- 5.1.1. Lesion morphology



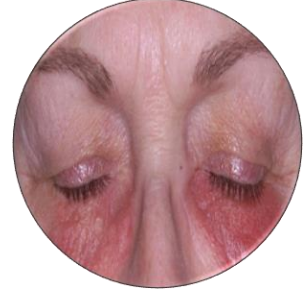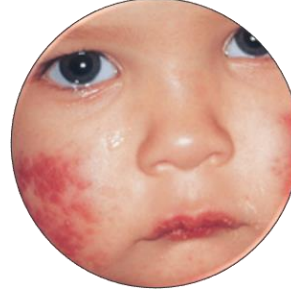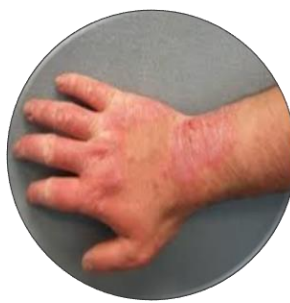- a. Acute ACD lesions consist of erythematous, indurated, scaly plaques. Vesiculation and bullae may be seen in severe cases. Edema may be prominent in areas in which the skin is thin, such as the eyelids, lips, and genitalia.



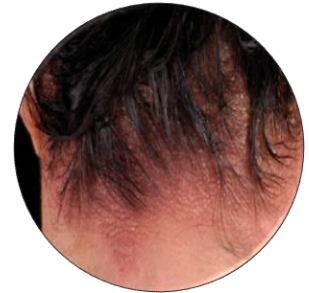- b. Repeated or continued exposure to allergens results in chronic disease. The skin becomes dry, scaly, and thicker as a result of acanthosis, hyperkeratosis, edema, and cellular infiltration in the dermis. Lichenification and fissuring may develop later.
- c. Secondary changes include excoriation or impetiginization. Subacute dermatitis has a mixture of both acute and chronic features

5.1.2. Lesion distribution ACD is typically localized to the skin areas that come in contact with the allergen. However, patchy or diffuse distributions may occur, depending upon the nature of the allergen or secondary transfer of the allergen from the primary site of contact to distant skin areas:

- a. The involvement of hands, face, or eyelids, which most commonly come in contact with the environment, occurs most frequently in ACD.

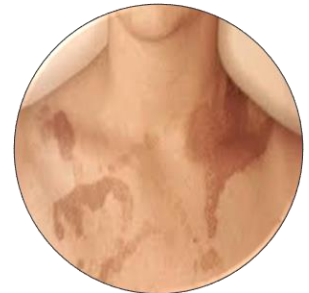

- b. Allergens applied to the scalp, including hair dyes and shampoos, may elicit dermatitis in adjacent areas.

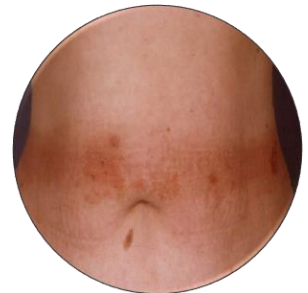

- c. Facial lesions may result from direct contact with cosmetic products or tools or from involuntary transfer of allergens to the face (e.g., eyelid ACD from nail polish).

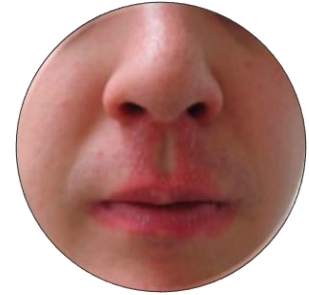- d. A pendant-like distribution of lesions (berloque dermatitis) in the neck and chest suggests a reaction to fragrances in perfumes and lotions.



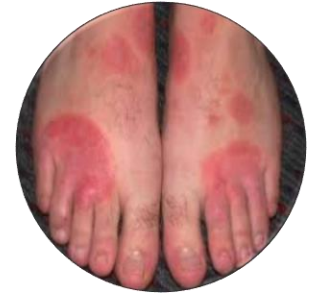- e. A diffuse or patchy dermatitis of the trunk, often with accentuation in the axillary folds, may be caused by cloth dyes or textiles. Rubber components may induce ACD at the site of contact with elastic waistbands.



f. Periorificial ACD may be induced by fragrances, detergents, or preservatives in hygiene products, including moist wipes.



g. Dermatitis involving the dorsal aspect of the foot suggests ACD related to shoe chemicals (e.g., rubber accelerators or potassium dichromate).



h. Involvement of photo-exposed areas suggests photo-allergic contact dermatitis.

i. Occupational ACD frequently involves the hands and requires a careful ascertainment of occupation-specific exposures

## 6. SYMPTOMS

6.1. The dominant symptom of ACD is itch. However, ACD may cause a variety of other symptoms, including burning, stinging, or pain.

## 7. RED FLAGS

- 7.1. Non-blanching rash in an unwell patient
- 7.2. Areas of rapidly worsening, painful eczema
- 7.3. Possible fever, lethargy or respiratory distress
- 7.4. Clustered blisters consistent with early-stage cold sores

- 7.5. Punched-out erosions (circular, depressed, ulcerated lesions) usually 1–3 mm that are uniform in appearance (these may coalesce to form larger areas of erosion with crusting)
- 7.6. Recurring infections
- 7.7. Spreading from broken skin (such as venous leg ulcers)
- 7.8. Recent tick bite (especially if in a known geographical risk area for Lyme disease)
- 7.9. Pregnancy
- 7.10. Involvement of >20% of the body surface

## **8. DISEASE COURSE**

- 8.1. If left untreated, ACD can evolve from an acute form to a subacute and then chronic eczematous dermatitis. Chronic dermatitis can negatively impact an individual's health related quality of life, particularly in social functioning and psychological wellbeing.
- 8.2. Successful allergen avoidance can result in clearance of ACD. Persistence of dermatitis in the face of dutiful allergen avoidance suggests an alternative diagnosis (e.g., systemic medication allergy, cutaneous lymphoma) or concurrent diagnosis (i.e., atopic dermatitis).

## 9. DIAGNOSIS

9.1. The diagnosis of ACD is usually made clinically based on the appearance and location of the lesions. This can be done by virtual video consultation. The diagnosis of ACD is based on a combination of:

9.1.1. Clinical features (morphology, location, and symptoms) of the eruption

9.1.2. History of exposure to a putative allergen during work, hobbies, or home activities

9.1.3. Lack of recurrence after empirical treatment of the dermatitis and avoidance of the suspected allergen If diagnosis can't be done by these, then patient should be referred for

9.1.4. Patch testing results

9.1.5. Laboratory tests and/or histopathologic examination

9.2. Clues from clinical examination

9.2.1. The morphology, regional distribution, and temporal course of dermatitis frequently suggest the diagnosis of ACD. The typical appearance of ACD is a well-demarcated, pruritic, eczematous eruption localized to the area of skin that comes in contact with the allergen. The eruption may be acute, with vesiculation and weeping, or chronic (lichenified or scaly plaques). The eruption may not remain anatomically limited to the initial site of contact. For example, a patient with a neomycin contact allergy

may exhibit a modest eruption at the site of application on the torso and a diffuse, concomitant dermatitis of the face due to passive transfer of the allergenic ointment to the face. Body washes or shampoos or cloth dyes and textiles may cause a patchy or diffuse dermatitis.

9.2.2. Less commonly, ACD may present with a photosensitivity reaction: The eruption is limited to photo-exposed skin areas and follows the application of sunscreens, fragrances, or topical nonsteroidal anti-inflammatory drugs (NSAIDs).

9.3. History — A comprehensive, multiyear history is helpful for the diagnosis of ACD. The source of contact with allergens may be identified by reviewing the patient's activities, including occupation and hobbies. Products and objects for personal use, including prescription or over the-counter topical preparations, cosmetics and toiletries, hair dyes, fragrances, eyeglasses, gloves, and clothing, should be reviewed. A patient's recall may not be complete and revisiting the history after obtaining the results of patch testing may be useful. A history of long-term exposure to an allergen does not rule out contact allergy, since multiple exposures are typically necessary for sensitization and dermatitis to occur. In addition, an individual's susceptibility to ACD may change over time because of aging, customs, or comorbidities (e.g., stasis dermatitis and leg ulcers). Infrequently, sensitization may occur after a single exposure. Occupational history is also important. Health professionals, chemical

industry workers, beauticians and hairdressers, machinists, and construction workers have an increased risk of developing occupational ACD. However, exposure to common industrial allergens, including cements, glues, plasters, and solvents, may also occur at home. A history of improvement during weekends or holidays suggests an occupational origin, whereas worsening during weekends or holidays suggests recreational exposure to allergens. A seasonal variation may indicate photo-aggravation or photo-allergy. A previous history of contact dermatitis may provide a clue to the origin of a relapse. For example, earring dermatitis may precede nickel dermatitis of the hands by several years. Patients with ACD often report a history of atopy (childhood flexural eczema, asthma, hay fever, or conjunctivitis).

- 9.4. Response to empiric therapy — When the possible offending allergen is identified on the basis of clinical features and history, response to empiric therapy may avoid the need for patch testing. Improvement or resolution of the dermatitis with allergen avoidance and empiric treatment supports the diagnosis of ACD
- 9.5. Patch testing — Patch testing is an essential investigation in patients with persistent eczematous eruptions when contact allergy is suspected or cannot be ruled out. Patch testing may help to identify allergens that should be avoided.
- 9.6. Laboratory tests and biopsy — Laboratory tests are not routinely necessary in the evaluation of patients for ACD but may be helpful in excluding other disorders with similar clinical features. For example, a KOH examination of scale from the eruption

or swab cultures may rule out a fungal or bacterial infection. Histologic examination on itself may provide little help in differentiating ACD from other eczematous dermatitides (including irritant contact dermatitis (ICD), atopic, nummular, dyshidrotic, and seborrheic dermatitis), since all present eosinophilic spongiosis as the key feature. However, histologic examination may be helpful when the diagnosis is not clear.

9.7. The histology of ACD mirrors the clinical picture.

9.7.1. In acute ACD, the epidermis is of normal thickness, and spongiosis (intercellular edema leading to the disruption of intercellular adhesion and formation of vesicles) is the dominant feature. An additional feature is the exocytosis of lymphocytes and eosinophils into spongiotic foci. The upper dermis contains an infiltrate of lymphocytes, histiocytes, and eosinophils, with perivascular accentuation.

9.7.2. In subacute ACD, there are mild to moderate spongiosis, moderate acanthosis (epidermal hyperplasia from increased mitotic activity of keratinocytes), and a denser dermal lymphohistiocytic infiltrate.

9.7.3. Chronic lesions may show prominent epidermal acanthosis with hyperkeratosis and areas of parakeratosis. Spongiosis may be present focally but often is minimal. The inflammatory infiltrate is sparse.



## 10. DIFFERENTIAL DIAGNOSIS

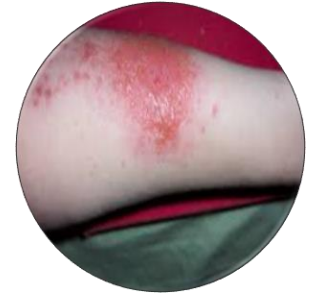- 10.1. ACD can mimic or complicate other types of eczema and other dermatoses. Differentiating ACD from irritant contact dermatitis (ICD) is particularly difficult since they have a similar clinical morphology. Patch testing may be useful to confirm the diagnosis of ACD. There is no specific test for the diagnosis of ICD.
- 10.2. Refer to APPENDIX 1 for the Summary of Differential Diagnoses.

## 11. MANAGEMENT

- 11.1. Refer to APPENDIX 2 for the Virtual Management of Allergic Contact Dermatitis Algorithm
- 11.2. The role of atopy in ACD is controversial, although several studies report a high rate of positive patch tests among atopic individuals. The optimal management of ACD requires a multipronged approach:
- 11.2.1. Identification and avoidance of the offending allergen
  - 11.2.2. Alternatives to offending products
  - 11.2.3. Treatment of skin inflammation
  - 11.2.4. Restoration of the skin barrier
  - 11.2.5. Skin protection The identification of the offending allergen is a key step in the management of ACD. Although the offending allergen is often identified through a detailed history, patch testing may be necessary to identify specific antigens.

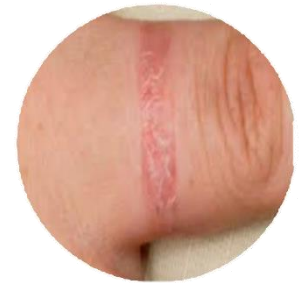11.3. Avoidance Education of patients on avoidance of offending substances and recommendation of alternative, allergen-free products are a critical part of the management of patients with ACD.

11.4. Common contact allergens Plants — The avoidance measures for contact allergy to plants of the Toxicodendron genus (poison ivy, oak, and sumac) are discussed separately.



11.5. Nickel

Nickel is found in alloys and plated objects, including jewelry, buttons, zippers, coins, keys, scissors, children's toys, cell phones, handheld computers, and metal tools.



Providing nickel-sensitive patients with a list of objects that may contain nickel may be helpful. Since jewelry (including some yellow and white gold) and metal components of clothing are the most common sources of nickel that are in prolonged contact with the skin, several avoidance measures have been suggested to limit nickel exposure from these sources.

Coating a nickel object with a physical barrier may prevent the release of nickel ions. The application of a clear barrier (eg, Nickel Guard) or clear nail polish to the buttons and rivets of jeans may prevent nickel release through at least two wash and dry cycles. As an alternative, iron-on patches may be applied on clothes to cover metal

parts that come in contact with the skin. Another physical barrier is duct tape. This can adhere to the inside of buttons or snaps, is inexpensive, easy to apply, and widely available. Chemical barriers for nickel include chelating and nonchelating barrier creams. Barrier creams containing agents such as disodium ethylenediamine tetraacetate (EDTA) act by chelating the positive ionic charge and rendering the metal inactive. Nonchelating creams may prevent the penetration of nickel through the skin.

#### 11.6. Cosmetics and personal care products

Although cosmetics and personal care products contain a high number of chemical ingredients, only a few of them are responsible for most cases of ACD. These include:

- 11.6.1. Fragrances
- 11.6.2. Preservatives (eg, quaternium-15, parabens, MI (methylisothiazolinone) or MCI/MI [the combination of methylchloroisothiazolinone and methylisothiazolinone, which is marketed as Kathon CG or Kathon WT] , thimerosal)
- 11.6.3. Excipients (eg, propylene glycol, lanolin, or colorants)
- 11.6.4. Glues (eg, acrylates in nail products)
- 11.6.5. Sunscreens
- 11.6.6. Hair dyes (para-phenylenediamine and derivatives)
- 11.6.7. Surfactants (cocamidopropyl betaine, decyl glucosides)

11.7. Occupational avoidance measures Avoidance in the workplace requires a more complex strategy. Several general measures may be adopted in the workplace to reduce exposure to chemicals, including:

- 11.7.1. Substitution of safer alternatives for allergenic materials
- 11.7.2. Automation
- 11.7.3. Process enclosure
- 11.7.4. Use of equipment for handling substances
- 11.7.5. Keeping a safe working distance
- 11.7.6. Washing promptly any chemical exposures from the skin
- 11.7.7. Using protective clothing and gloves

Protective gloves can reduce or eliminate exposure of the hands to hazardous substances. Gloves are ideally selected on the basis of the glove permeation and degradation properties and nature of the compounds that are manipulated. Multilayer laminate gloves, which incorporate a hydrophilic/polar layer between two hydrophobic/nonpolar layers, usually provide a high level of protection against a wide range of chemicals. Manufacturers of protective gloves provide lists of applications, hazards, and chemicals for which their gloves have been tested (eg, [www.bestglove.com](http://www.bestglove.com) or [www.ansell.com](http://www.ansell.com)). However, gloves, particularly rubber gloves, contain allergens that may worsen

hand dermatitis in some patients. Education on the proper way to put on and take off gloves is required to minimize exposures.

#### 11.8. Skin protection

Irritant contact dermatitis is often associated with or precedes the development of ACD. Prework (barrier) creams and after-work (emollients) creams appear to confer some degree of protection against irritant contact dermatitis, although evidence from randomized trials is limited. The substitution of milder detergents for abrasive or irritating cleansers and the application of allergen-free emollients (eg, petrolatum-based emollients) after each hand washing may reduce the risk of hand dermatitis at the workplace. The regular application of emollients to normal skin after repeated exposure to irritants may help to maintain the skin barrier function. Emollients may be liberally used as an adjunct to corticosteroids in the treatment of ACD, particularly chronic, lichenified dermatitis.

#### 11.9. Pharmacological treatment

11.9.1. Although avoidance of the offending allergen is the mainstay of management of ACD, treatment is required in most cases to achieve rapid control of symptoms. The treatment of ACD via teleconsultation are as below:

11.9.2. Topical corticosteroids – Topical low to medium potency corticosteroids are the first line treatment for localized ACD. (Refer Table (1): summary

of the different Topical corticosteroid preparations, in Seborrheic Dermatitis)

11.9.3. Topical calcineurin inhibitors – Topical tacrolimus or pimecrolimus may be an alternative to topical corticosteroids in the management of chronic, localized ACD; localized ACD resistant to topical corticosteroids; ACD involving the face or intertriginous areas; and ACD induced by topical corticosteroids. The efficacy of topical tacrolimus in ACD has been evaluated in randomized trials of experimentally induced nickel contact dermatitis . In one study, tacrolimus 0.1% ointment applied twice daily was more effective than placebo in clearing the eruption over eight weeks of continued exposure to the allergen. The onset of action of tacrolimus is slower than for potent topical corticosteroids. Local side effects of topical calcineurin inhibitors include burning and stinging at the site of application.

11.9.4. Other topical treatments – Soothing and drying agents may be useful for reduction of discomfort and pruritus in acute ACD. These include aluminum acetate compresses, calamine lotion, and colloidal oatmeal compresses or baths.

11.10. We recommend a face-to-face assessment If the following is needed:

11.10.1. High potency topical corticosteroid

11.10.2. Systemic corticosteroids – Oral corticosteroids are the first line treatment for ACD involving >20 percent of the body surface area or for acute ACD involving the face, hands, feet or genitalia if quick relief is desired (eg, involvement of the eyelids). Oral corticosteroids for ACD have not been studied in randomized trials. However, in clinical experience they are frequently beneficial in the treatment of poison ivy dermatitis, a common form of ACD.

11.10.3. Phototherapy – Phototherapy is a therapeutic option in patients with chronic ACD that is unresponsive to topical or oral corticosteroids. Small observational studies of patients with chronic hand eczema of various etiologies demonstrated clinical improvement with PUVA or narrowband UVB. Narrowband UVB is more convenient for the patient and associated with fewer side effects than PUVA.

11.10.4. Systemic immunosuppressive agents – Rarely, in cases of chronic ACD, azathioprine, mycophenolate mofetil, and cyclosporine have been used. Situations such as airborne composite dermatitis or photodermatitis, where allergen avoidance is impossible, are examples.

#### 11.11. Chronic ACD

We suggest intermittent high-potency topical corticosteroids for long-term control of chronic ACD involving the hands, feet, or nonflexural areas. Breakdown of the skin

barrier (atrophy) is a complicating factor in many cases of chronic ACD, which is exacerbated by overuse of topical corticosteroids. Every effort should be made to minimize continuous use of these agents beyond two to four weeks. Topical calcineurin inhibitors may be an alternative to topical corticosteroids in the management of chronic localized ACD resistant to topical corticosteroids and ACD induced by topical corticosteroids. They may be particularly useful in "sensitive-skin" locations (eg, the face or intertriginous areas). However, topical calcineurin inhibitors are expensive and there is little evidence to determine the optimal regimen. We suggest that calcineurin inhibitors (tacrolimus 0.1% ointment or pimecrolimus 1% cream) be applied twice daily to affected areas until resolution. They can be restarted if there is a recurrence.

## 12. SUMMARY AND RECOMMENDATIONS

The management of allergic contact dermatitis (ACD) consists of:

- 12.1. Identification of the offending allergen, avoidance, and treatment of skin inflammation.
- 12.2. Education about avoidance of offending substances and recommendations for alternative, allergen-free products are a critical part of the management of patients with ACD.



- 12.3. Medium- or low-potency topical corticosteroids for mild to moderate ACD of the face and flexural areas applied once or twice daily for one to two weeks. Topical calcineurin inhibitors are an alternative applied twice daily until resolution.
- 12.4. Suggest systemic rather than topical corticosteroids for:
- 12.4.1. Acute and extensive ACD involving the face if topical corticosteroids are ineffective or if quick relief is desired (eg, for eyelid involvement)
  - 12.4.2. ACD that involves >20 percent of the body surface area.
  - 12.4.3. ACD that involves <20 percent of the body surface area and is disabling or has not responded to treatment with topical corticosteroids or calcineurin inhibitors.
  - 12.4.4. Treatment is started with prednisone (or equivalent dose of other systemic corticosteroids at a dose of 0.5 to 1 mg/kg (maximum 60 mg per day) per day for seven days. The dose may be reduced by 50% in the next five to seven days and then tapered and discontinued over the following two weeks.
- 12.5. Phototherapy and systemic immunosuppressive medications are therapeutic options in patients with chronic ACD that is unresponsive to topical or oral corticosteroids. Narrowband UVB is more convenient for the patient and associated with fewer side effects than PUVA.

- 12.6. Intermittent high-potency topical corticosteroids rather than emollients alone for long-term control of chronic ACD involving the hands, feet, or non-flexural areas. The topical steroid is applied once daily three times per week on alternate days. Topical calcineurin inhibitors may be helpful in chronic localized ACD that is not responsive to topical corticosteroids or that is induced by topical corticosteroids.

### 13. REFERRAL CRITERIA

- 13.1. Refer to Family Physician

Refer to APPENDIX 1 for Referral Criteria

- 13.2. Refer to Dermatologist

- 13.2.1. Severe or refractory allergic contact dermatitis
- 13.2.2. Allergic contact dermatitis in immunocompromised patients
- 13.2.3. Psychosocial problems related to atopic eczema
- 13.2.4. Non-blanching Rash in an unwell patient
- 13.2.5. Areas of rapidly worsening, painful eczema
- 13.2.6. Possible fever, lethargy or respiratory distress (possibly to be referred to ER)
- 13.2.7. Clustered blisters consistent with early-stage cold sores
- 13.2.8. Punched-out erosions (circular, depressed, ulcerated lesions) usually 1–3 mm that are uniform in appearance (these may coalesce to form larger areas of erosion with crusting)




- 13.2.9. Recurring infections
- 13.2.10. Spreading from broken skin (such as venous leg ulcers)
- 13.2.11. Recent tick bite (especially if in a known geographical risk area for Lyme disease)
- 13.2.12. Pregnancy
- 13.2.13. Involvement of > 20% of the body surface
- 13.2.14. If High potency steroid is needed




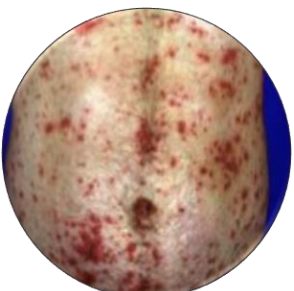
## REFERENCES

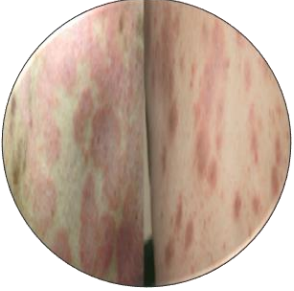
1. Brod, B. (2019). *Management of allergic contact dermatitis*. [online] Uptodate.com.  
Available at: [https://www.uptodate.com/contents/management-of-allergic-contact-dermatitis?search=allergic%20contact%20dermatitis&source=search\\_result&selectedTitle=1~116&usage\\_type=default&display\\_rank=1](https://www.uptodate.com/contents/management-of-allergic-contact-dermatitis?search=allergic%20contact%20dermatitis&source=search_result&selectedTitle=1~116&usage_type=default&display_rank=1) [Accessed 25 Dec. 2019].
2. Yiannias, J. (2019). *Clinical features and diagnosis of allergic contact dermatitis*.  
[online] Uptodate.com. Available at: [https://www.uptodate.com/contents/clinical-features-and-diagnosis-of-allergic-contact-dermatitis?search=allergic%20contact%20dermatitis&source=search\\_result&selectedTitle=2~116&usage\\_type=default&display\\_rank=2](https://www.uptodate.com/contents/clinical-features-and-diagnosis-of-allergic-contact-dermatitis?search=allergic%20contact%20dermatitis&source=search_result&selectedTitle=2~116&usage_type=default&display_rank=2).

## APPENDICES

### APPENDIX 1 – DIFFERENTIAL DIAGNOSIS

| No. | Diagnosis                   | Clinical Presentation  | Image   |
|-----|-----------------------------|--|---|
| 1   | Atopic dermatitis           | <ul style="list-style-type: none"> <li>Flexural areas, face, eyelids, and hands frequently involved</li> <li>Personal or family history of flexural eczema, asthma, allergic rhinitis, or hay fever during infancy or childhood</li> </ul>                           |    |
| 2   | Irritant contact dermatitis | <ul style="list-style-type: none"> <li>History of irritant exposure</li> <li>More demarcated and less itchy than allergic contact dermatitis</li> <li>Patch testing usually negative; may coexist with allergic contact dermatitis</li> </ul>                        |   |
| 3   | Seborrheic dermatitis       | <ul style="list-style-type: none"> <li>Greasy, scaly plaques in the central part of the face</li> <li>Frequent involvement of scalp, eyebrows, and eyelids</li> <li>Central chest and folds sometimes involved</li> <li>Absence of edema and vesiculation</li> </ul> |  |
| 4   | Dyshidrotic eczema          | <ul style="list-style-type: none"> <li>Recurrent vesicular eczema of the hands and/or feet</li> <li>Deep-seated, multilocular vesicles on the sides of the digits and on palmar or plantar skin</li> <li>Dorsal surfaces usually not involved</li> </ul>             |  |

|   |   |   |   |
|---|---|---|---|
| 5 | Psoriasis                                       | <ul style="list-style-type: none"> <li>• Demarcated, erythematous, and scaly plaques; frequent involvement of elbows and knees; nail pitting may be seen at close inspection</li> <li>• Absence of vesiculation, but pustules may be present on palms and soles</li> <li>• When limited to palms and soles, may be difficult to distinguish from chronic allergic contact dermatitis</li> </ul> |    |
| 6 | Stasis dermatitis                               | <ul style="list-style-type: none"> <li>• Medial aspects of lower legs usually involved; skin color changes are frequent</li> <li>• Other signs of chronic venous insufficiency usually present</li> <li>• Persistent stasis dermatitis suggests secondary contact sensitization</li> </ul>  |    |
| 7 | Asteatotic eczema (eczema craquelé)             | <ul style="list-style-type: none"> <li>• Crackled patches of dry skin on the lower legs</li> <li>• Lack of inflammation</li> </ul>  |  |
| 8 | Tinea manuum                                    | <ul style="list-style-type: none"> <li>• Typically unilateral and asymmetrical</li> <li>• Inflammatory edge</li> <li>• Sometimes associated with an autoeczematization reaction</li> </ul>  |  |
| 9 | Autoeczematization (autosensitization) reaction | <ul style="list-style-type: none"> <li>• Diffuse, pruritic, papulovesicular eruption</li> <li>• be associated with allergic contact dermatitis, stasis dermatitis, and bacterial or fungal infection</li> </ul>   |  |

|    |  |  |   |
|----|--|--|---|
| 10 | Mycosis fungoides (patch and plaque stage) | <ul style="list-style-type: none"> <li>Scaly patches or plaques, often pruritic, most frequently located on the trunk</li> <li>History of lesions waxing and waning over years</li> <li>Absence of edema and vesiculation</li> </ul> |  |
|----|--|--|---|

## APPENDIX 2 – VIRTUAL MANAGEMENT OF ALLERGIC CONTACT DERMATITIS ALGORITHM

