

<ul style="list-style-type: none">• Electronic copy is controlled under document control procedure. Hard copy is uncontrolled & under responsibility of beholder.• It is allowed ONLY to access and keep this document with who issued, who is responsible and to whom it is applicable.• Information security code: <input checked="" type="checkbox"/> Open <input type="checkbox"/> Shared -Confidential <input type="checkbox"/> Shared-Sensitive <input type="checkbox"/> Shared-Secret	<ul style="list-style-type: none">• النسخة الإلكترونية هي النسخة المضبوطة وفق إجراء ضبط الوثائق- النسخ الورقية غير مضبوطة وتقع على مسؤولية حاملها.• يسمح بالوصول وباحتفاظ بهذه الوثيقة مع مصدرها أو مع المسؤول عن تطبيقها أو مع المطبق عليهم.• تصنيف امن المعلومات: <input checked="" type="checkbox"/> بيانات مفتوحة <input type="checkbox"/> مشارك -خاص <input type="checkbox"/> مشارك -حساس <input type="checkbox"/> مشارك -سري
--	--

DHA TELEHEALTH CLINICAL GUIDELINES

FOR VIRTUAL MANAGEMENT

OF TINEA PEDIS – 48

Version 1

Issue date: 27/07/2021

Effective date: 27/09/2021

Health Policies and Standards Department

Health Regulation Sector (2021)

INTRODUCTION

Dubai Health Authority (DHA) is the responsible entity for regulating, licensing and monitoring health facilities and healthcare professionals in the Emirate of Dubai. The Health Regulation Sector (HRS) is an integral part of DHA and was founded to fulfil the following overarching strategic objectives:

Objective #1: Regulate the Health Sector and assure appropriate controls are in place for safe, effective and high-quality care.

Objective #2: Position Dubai as a global medical destination by introducing a value-based, comprehensive, integrated and high-quality service delivery system.

Objective #3: Direct resources to ensure happy, healthy and safe environment for Dubai population.

ACKNOWLEDGMENT

This document was developed for the Virtual Management of Tinea Pedis (Athlete's Foot) in collaboration with Subject Matter Experts. The Health Policy and Standards Department would like to acknowledge and thank these professionals for their dedication toward improving the quality and safety of healthcare services.

The Health Regulation Sector

Dubai Health Authority

TABLE OF CONTENTS

EXECUTIVE SUMMARY	4
DEFINITIONS/ABBREVIATIONS	6
1. BACKGROUND	7
2. SCOPE	8
3. PURPOSE	8
4. APPLICABILITY	8
5. RECOMMENDATIONS	9
6. DIFFERENTIAL DIAGNOSIS	11
7. RED FLAGS AND REFERRAL CRITERIA TO SPECIALISTS	11
8. MANAGEMENT AND INVESTIGATIONS	12
9. TREATMENT	13
REFERENCES	18
APPENDICES	19

EXECUTIVE SUMMARY

Telehealth is based on Evidence Based Practice (EBP) which is the conscientious, explicit and judicious use of current best evidence in making decisions about the care of the individual patient.

It means integrating individual clinical expertise with the best available external clinical evidence and guidelines from systematic research.

EBP is important because it aims to provide the most effective care virtually, with the aim of improving patient outcomes. As health professionals, part of providing a professional service is ensuring that practice is informed by the best available evidence.

This guideline is presented in the format comprising of clinical history/symptoms, differential diagnosis, investigations and management. Identification of 'Red Flags' or serious conditions associated with the disease is an essential part of this telehealth guideline as it aids the physician to manage patients safely and appropriately by referrals, if indicated during virtual telehealth assessment, to ER, family physicians or specialists for a face to face management.

The primary purpose of this Telehealth Guideline is to prove the health physicians, who will be managing patients virtually, with a summary of the best available evidence for the virtual management of this very common condition among adults.

Athlete's foot, also known tinea pedis, is a common skin infection caused by a fungus. Tinea commonly presents as an oval or annular lesion with a raised red edge. Other influences, such as steroids, may also cause a different appearance, which can make diagnosis less certain. In athlete's foot, the usual presentation in acute setting is moist, peeling areas between the toes, most

commonly the fourth and fifth toes. The skin may split, be painful and open to secondary infection (see picture below)

However, in chronic tinea pedis, the skin can be dry, powdery and tends to peel leaving crescentic scales. Often just one foot is affected, which helps to differentiate it from psoriasis. It develops slowly and is often presumed to be dry skin. Tinea pedis is usually caused by *Trichophyton rubrum*, *Epidermophyton floccosum* or *T mentagrophytes*.

This guideline also identifies key “Red Flags” or serious symptoms associated with tinea pedis which warrant a referral to specialist for further face-to-face management.

DEFINITIONS/ABBREVIATIONS

Virtual Clinical Assessment: Is the evaluation of the patient's medical condition virtually via telephone or video call consultations, which may include one or more of the following: patient medical history, physical examination and diagnostic investigations.

Patient: The person who receives the healthcare services or the medical investigation or treatment provided by a DHA licensed healthcare professional.

ABBREVIATIONS

DHA	:	Dubai Health Authority
EBP	:	Evidence Based Practice
ER	:	Emergency Room
KPI	:	Key Performance Indicator

1. BACKGROUND

1.1. Dermatophyte infections are common worldwide, and dermatophytes are the prevailing causes of fungal infection of the skin, hair, and nails. These infections lead to a variety of clinical manifestations, such as:

1.1.1. Tinea corporis – Infection of body surfaces other than the feet, groin, face, scalp hair, or beard hair

1.1.2. Tinea pedis – Infection of the foot

1.1.3. Tinea cruris – Infection of the groin

1.1.4. Tinea capitis – Infection of scalp hair

1.1.5. Tinea unguium (dermatophyte onychomycosis) – Infection of the nail

1.2. Although the management of the above major clinical subtypes of dermatophytes infections are similar, however, this Telehealth Guideline will only focus on Tinea Pedis (*Athlete's Foot*).

1.3. Tinea pedis (also known as *athlete's foot*) is the most common dermatophyte infection. Tinea pedis may manifest as an interdigital, hyperkeratotic, or vesiculobullous eruption, and rarely as an ulcerative skin disorder. Interdigital tinea pedis is most common. Tinea pedis frequently is accompanied by tinea unguium, tinea cruris, or tinea manuum.

1.4. Etiology

- 1.4.1. Tinea pedis usually occurs in adults and adolescents (particularly young men) and is rare prior to puberty.
- 1.4.2. Common causes are *Trichophyton rubrum*, *Trichophyton interdigitale* (formerly *Trichophyton mentagrophtes*), and *Epidermophyton floccosum*. Infection is usually acquired by means of direct contact with the causative organism, as may occur by walking barefoot in locker rooms or swimming pool facilities.

2. SCOPE

- 2.1. Telehealth services in DHA licensed Health Facilities.

3. PURPOSE

- 3.1. To support the implementation of Telehealth services for patients with Tinea Pedis (Athlete's Foot) in Dubai Health Authority (DHA) licensed Health Facilities

4. APPLICABILITY

- 4.1. DHA licensed physicians and health facilities providing Telehealth services.
- 4.2. Exclusion for Telehealth services are as follows
 - 4.2.1. Emergency cases where immediate intervention or referral is required.
 - 4.2.2. Prescribe Narcotics, Controlled or Semi-Controlled medications.

5. RECOMMENDATIONS

5.1. Virtual Clinical Assessment

5.1.1. Commonly, tinea pedis patients describe pruritic, scaly soles and, often, painful fissures between the toes. Less often, patients describe vesicular or ulcerative lesions. Some tinea pedis patients, especially elderly persons, may simply attribute their scaling feet to dry skin.

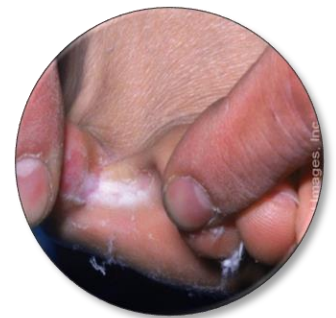5.1.2. It is important to conduct the teleconsultation via

- a. video or
- b. ask patient to send high resolution photo electronically if the consultation are conducted over the phone.

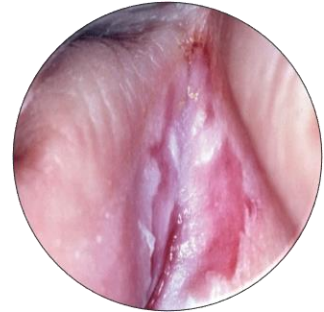5.1.3. Clinical features: There are 4 major clinical types of Tinea Pedis

a. Interdigital Tinea Pedis

- Interdigital tinea pedis manifests as pruritic, erythematous erosions or scales between the toes, especially in the third and fourth digital interspaces. Associated interdigital fissures may cause pain
- Tinea pedis with interdigital maceration
Erythema and white, macerated skin between the toes in a patient with tinea pedis.

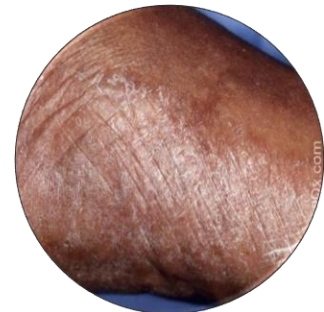


- Typical presentation of tinea pedis with peeling areas between the toes, most commonly the fourth and fifth toes. The skin is split, may be painful and open to secondary infection



b. Hyperkeratotic (moccasin-type) tinea pedis

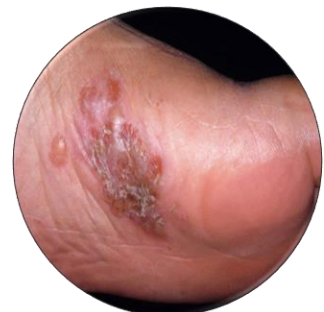- Hyperkeratotic tinea pedis is characterized by a diffuse hyperkeratotic eruption involving the soles and medial and lateral surfaces of the feet, resembling a "moccasin"



distribution. There is a variable degree of underlying erythema
Bullous tinea pedis: Vesicles and bullae on the plantar skin of a patient with tinea pedis.

c. Vesiculobullous (inflammatory) tinea pedis

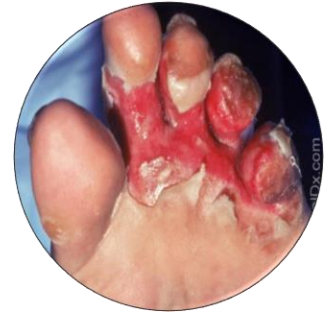- Vesiculobullous tinea pedis is characterized by a pruritic, sometimes painful, vesicular or bullous eruption with underlying erythema. The medial foot is often affected.



- Bullous tinea pedis: Vesicles and bullae on the plantar skin of a patient with tinea pedis.

d. Ulcerative tinea pedis

- Infrequently, tinea pedis may manifest with interdigital erosions and ulcers (ulcerative tinea pedis). This presentation is usually associated with



secondary bacterial infection. Ulcerative tinea pedis: :Extensive erosions in a patient with tinea pedis.

6. DIFFERENTIAL DIAGNOSIS

- 6.1. Refer to APPENDIX 1 for the summary of the Differential Diagnosis

7. RED FLAGS AND REFERRAL CRITERIA TO SPECIALISTS

- 7.1. Symptoms over face or neck.
- 7.2. Patients known to have had adverse reactions to topical and oral antifungal treatment.
- 7.3. Patient is in severe pain.
- 7.4. If the foot is red, hot and painful – which could be a sign of serious bacterial infections.
- 7.5. Patient has diabetes – foot problems can be more serious.
- 7.6. Patient is immunosuppressed (e.g. if on chemotherapy or long- term steroids.)

- 7.7. Toenails becoming black or discolored.
- 7.8. If fungal infections start to spread under the nails.
- 7.9. If the fungal infection spreads to other areas of the body.
- 7.10. Evidence of other infections (including pus exudate).
- 7.11. Patients who exhibit significant erosions, ulceration, or malodor in the affected area should be referred for a Gram stain and culture to evaluate for secondary bacterial infection and treatment.
- 7.12. Signs of systemic illness (fever, fatigue, swollen lymph glands)
- 7.13. Extensive areas of feet affected (both top and bottom)
 - 7.13.1. Toenails infected
 - 7.13.2. Severely inflamed
 - 7.13.3. Weeping or purulent
 - 7.13.4. Painful
 - 7.13.5. Disabling
- 7.14. No improvement after one week of previous appropriate antifungal therapy
- 7.15. Diagnosis is not clear, and that patient would require further investigation

8. MANAGEMENT AND INVESTIGATIONS

- 8.1. Refer to APPENDIX 2 for the Virtual Management of Tinea Pedis Algorithm
- 8.2. Investigation

- 8.2.1. Most often, further investigation may not be required. However, if the diagnosis is not certain after the video consultation, then patients should be referred for further investigations:
- a. Microscopy of skin and nail specimens may reveal hyphae and spores.
 - b. Fungal culture can identify the species but is not always reliable and it can take 6 weeks to obtain results.
 - c. Gram stain and culture to evaluate for secondary bacterial infection in patients who exhibit significant erosions, ulceration, or malodor in the affected.
 - d. Rarely, a biopsy may be needed if the case is atypical or not responding to treatment.

9. TREATMENT

9.1. Non-pharmacological Treatment

- 9.1.1. Patient Education: Patients with tinea pedis should be educated that reinfection can occur if they are re-exposed to dermatophytes. Therefore, in order to prevent reinfection, advice should be given to the patient about the following prevention measures:
- a. Good skin hygiene. Advise patients to wash their feet daily and dry the skin between toes thoroughly after washing. This is perhaps the most important point. It may be tempting for patients to put socks on when their feet are not quite dry but do explain that the soggy skin between the toes is then ideal for fungi to grow.

- b. Avoid sharing towels in communal changing rooms. Also, advice to wash towels frequently.
- c. Good nail hygiene.
- d. Avoiding prolonged wetting or dampness of the skin and feet.
- e. Avoiding trainers shoes, which can retain sweat and promote a warm, moist environment.
- f. Change or wash socks and shoes regularly. Fungi may multiply in flakes of skin in unwashed socks. Cotton socks and leather footwear are probably better than nylon socks and plastic footwear, which increase sweating.
- g. Ideally, patient should alternate between different shoes every 2-3 days to allow each pair to dry out fully after being worn.
- h. Old shoes are often the sources of reinfection and should be disposed of or treated with antifungal powders.
- i. Treatment of tinea pedis - helps prevent onychomycosis.
- j. Patients should be cautioned to wear protective footwear at communal pools and baths and should attempt to keep their feet dry by limiting occlusive footwear.
- k. When occlusive footwear is worn, wearing cotton socks and adding a drying powder with antifungal action in the shoes may be helpful.

- l. Ideally, patient should wear flip-flops or plastic sandals in communal changing rooms and showers. This prevents the soles of feet coming into contact with the ground, which may contain flakes of skin from other people.
- m. Ideally, when at home, patients should leave their shoes and socks off as much as possible to let the air get to feet. However, this may not be practical for some people.

9.2. Pharmacological Treatment

Treatment is recommended to alleviate symptoms (pruritus), reduce risk for secondary bacterial infection, and limit spread of the infection to other body sites or other individuals.

9.2.1. Topical antifungal therapy:

- a. Topical antifungal therapy is the treatment of choice for most patients. Systemic antifungal agents are primarily reserved for patients who fail topical therapy.
- b. Topical antifungal treatment is generally applied once or twice daily and continued for 4 weeks. Shorter treatment courses may be effective; high cure rates have been obtained with terbinafine 1% cream applied to interdigital tinea pedis for 1 week.

- c. Refer to APPENDIX 3 for Topical antifungal agents effective for Tinea Pedis

9.2.2. Oral antifungal therapy

- a. Patients requiring oral antifungal therapy are usually treated with terbinafine, itraconazole, or fluconazole. Typical treatment regimens for adults include:
 - Terbinafine (adult only): 250 mg per day for 2-6 weeks
 - Itraconazole: Adult: 100 mg once daily for 30 days, alternatively 200 mg twice daily for 7 days
 - Fluconazole: Adult: 50 mg daily for up to 6 weeks in tinea pedis; max. duration of treatment 6 weeks.
- b. Griseofulvin can also treat tinea pedis but may be less effective than other oral antifungals and requires a longer duration of therapy . In a systematic review, terbinafine was found more effective than griseofulvin, while the efficacy of terbinafine and itraconazole were similar. Therefore, it is not recommended to prescribe griseofulvin for tinea pedis.
- c. Patients with hyperkeratotic tinea pedis can benefit from combining antifungal treatment with a topical keratolytic, such as salicylic acid.

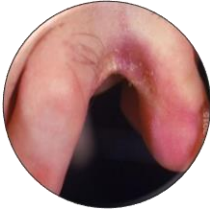
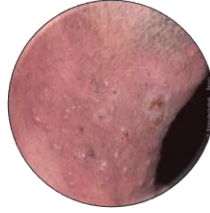


- d. Interventions that may help to reduce recurrences include use of desiccating foot powders, treatment of shoes with antifungal powder, and avoidance of occlusive footwear.





REFERENCES


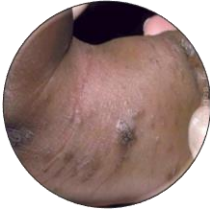
1. Crawford, F. and Hollis, S. (2020). *Topical treatments for fungal infections of the skin and nails of the foot*. [online] Uptodate.com. Available at: <https://www.uptodate.com/contents/dermatophyte-tinea-infections/abstract/9> [Accessed 5 Feb. 2020].
2. Dr Oliver Starr (2018). *Athlete's Foot (Tinea Pedis)*. [online] Patient.info. Available at: <https://patient.info/infections/fungal-infections/athletes-foot-tinea-pedis> [Accessed 11 Dec. 2019].
3. Goldstein, A. and Goldstein, B. (2019). *Dermatophyte (tinea) infections*. [online] Uptodate.com. Available at: https://www.uptodate.com/contents/dermatophyte-tinea-infections?search=athletes%20foot&source=search_result&selectedTitle=1~104&usage_type=default&display_rank=1 [Accessed 11 Dec. 2019].
4. Korting, H., Tietz, H., Bräutigam, M., Mayser, P., Rapatz, G. and Paul, C. (2020). *One week terbinafine 1% cream (Lamisil) once daily is effective in the treatment of interdigital tinea pedis: a vehicle-controlled study. LAS-INT-06 Study Group*. [online] Uptodate.com. Available at: <https://www.uptodate.com/contents/dermatophyte-tinea-infections/abstract/10> [Accessed 5 Feb. 2020].

APPENDICES

APPENDIX 1 – DIFFERENTIAL DIAGNOSIS

Interdigital Tinea Pedis	
	<p>Erythrasma</p> <p>Erythrasma: Interdigital scale and maceration on the foot</p>
	<p>Interdigital <i>Candida</i> infection (erosio interdigitalis blastomycetica)</p> <p>Candidal intertrigo of the finger web: Erosio interdigitalis blastomycetica (interdigital candidal infection) in a bartender whose hands were constantly wet. In the acute phase, erosio interdigitalis blastomycetica may have a more macerated appearance.</p>
Hyperkeratotic (moccasin-type) Tinea Pedis	
	<p>Atopic Dermatitis</p>
	<p>Chronic Contact Dermatitis</p> <p>Allergic Contact Dermatitis</p>
	<p>Chronic Palmoplantar (dyshidrotic) Eczema</p> <p>Dyshidrotic foot eczema Desquamation following vesicle desiccation in a patient with plantar dyshidrotic eczema</p>

	<p>Palmoplantar Psoriasis Erythematous, scaly plaques with fissures on the palms and soles.</p>
	<p>Pitted keratolysis This 20-year-old female with plantar hyperhidrosis exhibited asymptomatic cribriform pits on her soles. The feet were malodorous.</p>
	<p>Juvenile plantar dermatosis Shiny-appearing plantar skin with accentuation of the skin folds and fissures in a teenager with juvenile plantar dermatosis. Shiny and cracked appearance of the plantar skin in a child with juvenile plantar dermatosis.</p>
	<p>Keratolysis exfoliativa</p>
	<p>Keratodermas</p>
<p>Vesiculobullous (inflammatory) Tinea Pedis</p>	
	<p>Acute palmoplantar (dyshidrotic) eczema Multiple small vesicles and post-inflammatory hyperpigmentation on the foot.</p>
	<p>Acute Contact Dermatitis</p>

	<p>Palmoplantar pustulosis</p> <p>Pustules within an erythematous, scaly plaque on the foot.</p>
	<p>Scabies</p> <p>Erythematous and hyperpigmented papules and crusts on the foot of a child with scabies.</p>

Appendix 2 – VIRTUAL MANAGEMENT OF TINEA PEDIS ALGORITHM

Virtual Management of Tinea Pedis (Athlete's Foot) Algorithm

Rule Red Flags

- Symptoms over face or neck.
- Patients known to have had adverse reactions to topical and oral antifungal treatment.
- Patient is in severe pain.
- If the foot is red, hot and painful – which could be a sign of serious bacterial infections.
- Patient has diabetes – foot problems can be more serious.
- Patient is immunosuppressed (eg. if on chemotherapy or long- term steroids.)
- Toenails becoming black or discolored.
- If fungal infections start to spread under the nails.
- If the fungal infection spreads to other areas of the body.
- Evidence of other infections (including pus exudate).
- Patients who exhibit significant erosions, ulceration, or malodor in the affected area should be referred for a Gram stain and culture to evaluate for secondary bacterial infection and treatment.
- Signs of systemic illness (fever, fatigue, swollen lymph glands)
- Extensive areas of feet affected (both top and bottom)
 - Toenails infected
 - Severely inflamed
 - Weeping or purulent
 - Painful
 - Disabling
- No improvement after one week of previous appropriate antifungal therapy
- Diagnosis is not clear and that patient would require further investigation

Yes

Refer to
Specialist for
face-to-face
consultation

No

Symptoms typical of Tinea Pedis:

- White fissures, scaling, or maceration between the toes
- Area is inflamed, blistered, itchy or burning
- May cover soles of both feet and progress to sides and top of foot
- +/- previous diagnosis of tinea pedis by a Doctor

Yes

Management / Treatment

- Non-pharmacologic treatment: Provide patient education and advice
- Topical treatment
 - Clotrimazole* 1% cream/liquid/spray, apply topically BID to TID for at least 4 weeks.
 - Miconazole* 2% cream/spray/powder = topically BID and continue for 10 days after the skin is back to normal.
 - Terbinafine 1% cream, OD-BID for 1 week. Not suitable for children.

*agents of choice in pregnancy

- At least every 2 weeks follow-up until resolution of symptoms
- Refer if infection is not responding to treatment.

Appendix 3 - TOPICAL ANTIFUNGAL AGENTS EFFECTIVE FOR TINEA PEDIS

Drug	Route	Dose and duration	Preparations/Medicinal Forms
Terbinafine	Topical	Child: Not suitable for children Adult: Apply 1–2 times a day for up to 1 week, to be applied thinly.	Cream ▶ Terbinafine hydrochloride 10 mg per 1 gram (Terbinafine 1%)
Clotrimazole	Topical	Child: Apply 2–3 times a day Adult: Apply 2–3 times a day	Cream ▶ Clotrimazole 10 mg per 1 gram (1%) Liquid (solution) ▶ Canesten (clotrimazole 10 mg per 1 ml Canesten 1% solution) Spray ▶ Clotrimazole 10 mg per 1 ml Canesten Dermatological 1% spray
Miconazole	Topical	Child: Apply twice daily continuing for 10 days after lesions have healed Adult: Apply twice daily continuing for 10 days after lesions have healed	Cream ▶ Daktarin 2% (Miconazole nitrate 20 mg per 1 gram (2% cream)). Spray ▶ Daktarin (Miconazole nitrate 1.6 mg per 1 gram; 0.16% spray powder 100 gram Powder ▶ Daktarin (Miconazole nitrate 20 mg per 1 gram (2%) powder