

- Electronic copy is controlled under document control procedure. Hard copy is uncontrolled & under responsibility of beholder. • النسخة الإلكترونية هي النسخة المضبوطة وفق إجراء ضبط الوثائق- النسخ الورقية غير مضبوطة وتقع على مسؤولية حاملها.
- It is allowed ONLY to access and keep this document with who issued, who is responsible and to whom it is applicable. • يسمح بالوصول وباحتفاظ بهذه الوثيقة مع مصدرها أو مع المسؤول عن تطبيقها أو مع المطبق عليهم.
- Information security code:  Open  Shared -Confidential  Shared-Sensitive  Shared-Secret  مشارك -مشارك  بيانات مفتوحة  مشارك -خاص  مشارك -حساس  مشارك -سري

# DHA TELEHEALTH CLINICAL GUIDELINES

## FOR VIRTUAL MANAGEMENT

### OF IMPETIGO – 43

Version 2

Issue date: 21/02/2024

Effective date: 21/04/2024

Health Policies and Standards Department  
Health Regulation Sector (2024)

## INTRODUCTION

Health Regulation Sector (HRS) forms an integral part of Dubai Health Authority (DHA) and is mandated by DHA Law No. (14) of the year (2021) amending some clauses of law No. (6) of 2018 pertaining to the Dubai Health Authority (DHA), to undertake several functions including but not limited to:

- Developing regulation, policy, standards, guidelines to improve quality and patient safety and promote the growth and development of the health sector;
- Licensure and inspection of health facilities as well as healthcare professionals and ensuring compliance to best practice;
- Managing patient complaints and assuring patient and physician rights are upheld;
- Governing the use of narcotics, controlled and semi-controlled medications;
- Strengthening health tourism and assuring ongoing growth; and
- Assuring management of health informatics, e-health and promoting innovation.

The DHA Telehealth Clinical Guidelines aim to fulfil the following overarching DHA Strategic Priorities (2026):

- Pioneering Human-centered health system to promote trust, safety, quality and care for patients and their families.
- Make Dubai a lighthouse for healthcare governance, integration and regulation.

- Leading global efforts to combat epidemics and infectious diseases and prepare for disasters.
- Pioneering prevention efforts against non-communicable diseases.
- Become a global digital health hub.
- Foster healthcare education, research and innovation.

## ACKNOWLEDGMENT

The Health Policy and Standards Department (HPSD) developed this Guideline in collaboration with Subject Matter Experts and would like to acknowledge and thank these health professionals for their dedication toward improving quality and safety of healthcare services in the Emirate of Dubai.

### Health Regulation Sector

### Dubai Health Authority

## TABLE OF CONTENTS

<b>EXECUTIVE SUMMARY</b>	<b>5</b>
<b>DEFINITIONS/ABBREVIATIONS</b>	<b>6</b>
<b>1. BACKGROUND</b>	<b>7</b>
<b>2. SCOPE</b>	<b>7</b>
<b>3. PURPOSE</b>	<b>7</b>
<b>4. APPLICABILITY</b>	<b>8</b>
<b>5. RED FLAGS</b>	<b>8</b>
<b>6. HISTORY/SYMPTOMS</b>	<b>8</b>
<b>7. CLINICAL MANIFESTATIONS</b>	<b>10</b>
<b>8. DIAGNOSIS AND LABORATORY INVESTIGATIONS</b>	<b>11</b>
<b>9. DIFFERENTIAL DIAGNOSIS</b>	<b>13</b>
<b>10. REFERRAL CRITERIA</b>	<b>14</b>
<b>11. MANAGEMENT AND TREATMENT</b>	<b>15</b>
<b>12. PROGNOSIS AND POSTINFECTIOUS COMPLICATIONS</b>	<b>19</b>
<b>REFERENCES</b>	<b>21</b>
<b>APPENDICES</b>	<b>22</b>

## EXECUTIVE SUMMARY

Telehealth is based on Evidence Based Practice (EBP) which is the conscientious, explicit and judicious use of current best evidence in making decisions about the care of the individual patient.

It means integrating individual clinical expertise with the best available external clinical evidence and guidelines from systematic research

Impetigo is a contagious superficial bacterial infection observed most frequently in children ages 2 to 5 years, although older children and adults may also be affected. It may be classified as primary impetigo (direct bacterial invasion of previously normal skin) or secondary impetigo (infection at sites of minor skin trauma such as abrasions, minor trauma, and insect bites, or underlying conditions such as eczema). Pyoderma and impetigo contagiosa are sometimes used as synonyms for primary impetigo. The occurrence of secondary impetigo is sometimes referred to as "impetiginization." The infection usually occurs in warm, humid conditions and is easily spread among individuals in close contact; risk factors include poverty, crowding, poor hygiene, and underlying scabies. Carriage of group A *Streptococcus* (GAS; *Streptococcus pyogenes*) and *Staphylococcus aureus* predisposes to subsequent impetigo

This guideline is presented in the format comprising of clinical history/symptoms, differential diagnosis, investigations and management. Identification of 'Red Flags' or serious conditions associated with the disease is an essential part of this telehealth guideline as it aids the physician to manage patients safely and appropriately by referrals to ER, family physicians or specialists for a face to face management.

## DEFINITIONS/ABBREVIATIONS

**Virtual Clinical Assessment:** Is the evaluation of the patient's medical condition virtually via telephone or video call consultations, which may include one or more of the following: patient medical history, physical examination and diagnostic investigations.

**Patient:** The person who receives the healthcare services or the medical investigation or treatment provided by a DHA licensed healthcare professional.

## ABBREVIATIONS

<b>DHA</b>	:	Dubai Health Authority
<b>EBP</b>	:	Evidence Based Practice
<b>ER</b>	:	Emergency Room
<b>KPI</b>	:	Key Performance Indicator

## 1. BACKGROUND

### 1.1. Etiology

- 1.1.1. Intact skin is usually resistant to colonization or infection by bacteria such as *S aureus* or Group A Beta-hemolytic streptococci (GABHS). These types of bacteria can be introduced from the environment and only transiently colonize the cutaneous surface. Experimental studies have shown that inoculation of multiple strains of GABHS on to the surface of subjects did not produce cutaneous disease unless skin disruption had occurred.
- 1.1.2. The principal pathogen involved in impetigo is *S. aureus*. Beta-hemolytic streptococci (primarily group A, but occasionally other serogroups such as C and G) account for a minority of cases, either alone or in combination with *S. aureus*. Methicillin-resistant *S. aureus* is detected in some cases of impetigo.
- 1.1.3. Bullous impetigo is caused by strains of *S. aureus* that produce a toxin causing cleavage in the superficial skin layer (see *Bullous impetigo above*). Ecthyma is due to GAS.

## 2. SCOPE

- 2.1. Telehealth services in DHA licensed Health Facilities.

## 3. PURPOSE

- 3.1. To support the implementation of Telehealth services for patients with Impetigo in Dubai Health Authority (DHA) licensed Health Facilities

#### 4. APPLICABILITY

- 4.1. DHA licensed physicians and health facilities providing Telehealth services.
- 4.2. Exclusion for Telehealth services are as follows
  - 4.2.1. Emergency cases where immediate intervention or referral is required.
  - 4.2.2. Prescribe Narcotics, Controlled or Semi-Controlled medications.

#### 5. RED FLAGS

- 5.1. The following are considered as red flags for impetigo and need appropriate referral
  - 5.1.1. Extensive skin involvement
  - 5.1.2. Immunocompromised patient
  - 5.1.3. Patients with systemic complications
  - 5.1.4. Associated with headache, photophobia, neck stiffness and/or non-blanching rash
  - 5.1.5. Scalded skin appearance
  - 5.1.6. An unwell patient (adult or child)
  - 5.1.7. A potentially life-threatening superinfection which should be treated as a dermatologic emergency.

#### 6. HISTORY/SYMPTOMS

- 6.1. The presence or absence of associated symptoms can help clinicians develop a differential diagnosis. The most important initial questions to ask the patient include the following:



- 6.1.1. How long has the eruption or lesion been present?
- 6.1.2. How did it look when it first appeared, and how is it now different?
- 6.1.3. Where did it first appear, and where is it now?
- 6.1.4. What associated symptoms, such as itching, stinging, tenderness, or pain, are associated with the lesion?
- 6.1.5. Are any other family members affected or have a similar history?
- 6.1.6. Has the patient ever had this rash or lesion before? If so, what treatment was used, and what was the response?
- 6.1.7. What does the patient think cause the rash or lesion?
- 6.1.8. Is anything new or different (eg, medications, personal care products)?
- 6.1.9. How does the skin problem impact the patient?
- 6.1.10. What treatments have been used, and what was the response, this time and previously?
- 6.2. Additional questions that may be helpful include:
  - 6.2.1. Does the patient have any acute or chronic medical conditions?
  - 6.2.2. What medications does the patient take currently, what have he recently taken, including over-the-counter and herbal therapies?
  - 6.2.3. Is there a family history of skin disorders or skin cancer?
  - 6.2.4. What is the social history, including travel?
  - 6.2.5. Does the patient have any allergies?

6.2.6. Are there pets at home?

6.3. The following symptoms usually are absent in impetigo contagious but should be explored as they may be present in bullous impetigo:

6.3.1. Fever

6.3.2. Diarrhea

6.3.3. Generalized weakness

## 7. CLINICAL MANIFESTATIONS

Variants of impetigo include non-bullous impetigo, bullous impetigo, and ecthyma. Systemic symptoms are usually absent. Regional lymphadenitis may occur.

### 7.1. Non-bullous impetigo

7.1.1. Non-bullous impetigo is the most common form of impetigo. Lesions begin as papules that progress to vesicles surrounded by erythema. Subsequently they become pustules that enlarge and rapidly break down to form thick, adherent crusts with a characteristic golden appearance; this evolution usually occurs over about 1 week. Lesions usually involve the face and extremities. Multiple lesions may develop but tend to remain well localized. Refer to APPENDIX 1 for images.

### 7.2. Bullous impetigo

7.2.1. Bullous impetigo is a form of impetigo seen primarily in young children in which the vesicles enlarge to form flaccid bullae with clear yellow fluid,

which later becomes darker and more turbid; ruptured bullae leave a thin brown crust. Usually there are fewer lesions than in non-bullous impetigo, and the trunk is more frequently affected. Bullous impetigo in an adult with appropriate demographic risk factors should prompt an investigation for previously undiagnosed human immunodeficiency virus (HIV) infection. Bullous impetigo is due to strains of *S. aureus* that produce exfoliative toxin A, a toxin that causes loss of cell adhesion in the superficial epidermis by targeting the protein desmoglein 1. This mechanism is related to the pathophysiology of pemphigus, in which autoantibodies are directed against the same protein. Refer to APPENDIX 1 for images.

### 7.3. Ecthyma

7.3.1. Ecthyma is an ulcerative form of impetigo in which the lesions extend through the epidermis and deep into the dermis. They consist of "punched-out" ulcers covered with yellow crust surrounded by raised violaceous margins. Refer to APPENDIX 1 for images.

## 8. DIAGNOSIS AND LABORATORY INVESTIGATIONS

8.1. The diagnosis of impetigo often can be made on the basis of clinical manifestations. The key clinical findings of non-bullous impetigo, bullous impetigo, and ecthyma include:

- 8.1.1. Non-bullous impetigo – Papules, vesicles, and pustules that rapidly break down to form golden adherent crusts; often located on the face or extremities.
  - 8.1.2. Bullous impetigo – Flaccid, fluid-filled bullae that rupture and leave a thin brown crust; often located on the trunk.
  - 8.1.3. Ecthyma – "Punched-out" ulcers with overlying crusts and raised violaceous borders.
- 8.2. A Gram stain and culture of pus or exudate is recommended to identify whether *S. aureus* and/or a beta-hemolytic *Streptococcus* is the cause. In this case, patient should be referred for face-to-face consultation for this type of investigation. However, treatment may be initiated without these studies in patients with typical clinical presentations. Serologic testing for streptococcal antibodies is not useful for the diagnosis of impetigo:
- 8.2.1. The anti-streptolysin O (ASO) response is weak, likely because skin lipids suppress streptolysin O response.
  - 8.2.2. Anti-deoxyribonuclease B (anti-DNase B) and antihyaluronidase (AHT) response are more reliable than the ASO response following group A *Streptococcus* (GAS) skin infections.
- 8.3. However, serologic testing can be helpful in the setting of impetigo with subsequent presumed poststreptococcal glomerulonephritis.

## 9. DIFFERENTIAL DIAGNOSIS

9.1. The differential diagnosis of impetigo differs based upon the clinical presentation.

Gram stain and culture are useful for confirming the etiologic diagnosis.

9.1.1. Non-bullous impetigo – Skin conditions that may share features with non-bullous impetigo include a variety of inflammatory conditions that may present with localized areas of inflammation. Examples include contact dermatitis, tinea infection and eczema herpeticum and other herpes simplex virus infections. Recognition of the characteristic golden crust should raise suspicion for impetigo. Refer to APPENDIX 2 for images.

9.1.2. Bullous impetigo – Bullous impetigo should be differentiated from other blistering skin conditions. Examples include autoimmune blistering diseases (Refer to APPENDIX 3 for table of autoimmune mucocutaneous blistering diseases), acute contact dermatitis, bullous drug eruptions, burns, bullous insect bite reactions, varicella, and subcorneal pustular dermatosis. The progression from bullae to erosions with peripheral crust is characteristic of bullous impetigo. Refer to Appendix 2 for images.

9.1.3. Ecthyma – The differential diagnosis of ecthyma often includes other conditions that may cause localized ulcers, such as mycobacterial or deep

fungal infections or pyoderma gangrenosum. Ecthyma can be confused with ecthyma gangrenosum, a potentially life-threatening skin condition that occurs in patients with pseudomonal bacteremia. In ecthyma gangrenosum, painless erythematous or purpuric macules rapidly evolve into hemorrhagic vesicles or bullae that subsequently rupture to leave an ulcer with necrotic black eschar. Unlike ecthyma, patients with ecthyma gangrenosum are usually systemically ill. Refer to Appendix 2 for images.

## 10. REFERRAL CRITERIA

### 10.1. Referral to Emergency Department

10.1.1. Referral to the Emergency Department must be made if the patient is having the following associated symptoms:

- a. Neck stiffness
- b. Photophobia and/or non-blanching rash
- c. Patients with systemic complication
- d. Seem confused
- e. Scalded skin appearance
- f. A potentially life-threatening superinfection which should be treated as a dermatologic emergency.
- g. Looks unwell or hypotensive, clammy and feels weak (adult or child)

### 10.2. Referral to Family physician or Dermatologist

- 10.2.1. For the following, patient need to be referred to specialists:
- a. Persistent impetigo, not improving with medications
  - b. Recurrent symptoms
  - c. Have a fever that cannot be controlled
  - d. Needs further assessment or investigation
  - e. Patients with extensive skin involvement
  - f. Immunocompromised patient
  - g. Patients with skin allergies and eczema
  - h. Diagnosis is uncertain

## 11. MANAGEMENT AND TREATMENT

11.1. Refer to APPENDIX 4 for the Virtual Management of Impetigo

11.2. Non-pharmacological Management

11.2.1. Patient Education

Inform patients about early and proper care of predisposing factors (eg, insect bites, minor trauma). Recommend that patients properly cleanse and apply a topical antibiotic to minor skin traumas. Crusted lesions can be washed gently. Discourage touching the lesions. Handwashing is important for reducing spread among children, and other preventive

measures employed in reducing the spread of staphylococci may also be helpful

- 11.2.2. Return to work/school — Patient can return to work or school 24 hours after beginning an effective antimicrobial therapy. Draining lesions should be kept covered.

### 11.3. Pharmacological Management

Treatment of impetigo is important for reducing spread of infection, hastening the resolution of discomfort, and improving cosmetic appearance. Bullous and non-bullous impetigo can be treated with either topical or oral therapy. Topical therapy is used for patients with limited skin involvement, whereas oral therapy is recommended for patients with numerous lesions. Unlike impetigo, ecthyma should always be treated with oral therapy.

- 11.3.1. Limited impetigo — Topical therapy for impetigo should be administered if there are a limited number of lesions.

Topical therapy — Benefits of topical therapy include fewer side effects and lower risk for contributing to bacterial resistance compared with oral therapy. Mupirocin 2% is first-line treatments. Mupirocin can be used if MRSA infection is suspected. Topical fusidic acid can be effective for impetigo; however, evidence for increasing resistance of *S. aureus* to fusidic acid in locations where topical fusidic acid use is common has



made it a less favorable option for therapy. Dosages of topical medications (as per BNF Recommendations):

a. Mupirocin 2%:

Adult and child over 1 year, apply up to 3 times daily topically for up to 10 days. Note: *To avoid the development of resistance, mupirocin or fusidic acid should not be used for longer than 10 days*

b. Topical fusidic acid 2% cream

Apply 3–4 times daily topically. Suggested duration of treatment 7 days is usually adequate (max. 10 days).

Note: to avoid the development of resistance, fusidic acid should not be used for longer than 10 days.

Although the components of over-the-counter triple antibiotic ointments (consisting of bacitracin-neomycin-polymyxin B) have some activity against the organisms causing impetigo, they may not be as effective for treatment. Therefore, treatment of impetigo with these agents is not recommended. Bacitracin and neomycin can also cause contact dermatitis. In rare cases, bacitracin has been associated with allergic anaphylactoid reactions.

- 11.3.2. Extensive impetigo and ecthyma — Oral therapy should be administered to patients with numerous impetigo lesions or ecthyma.

Systemic antibiotics — Unless cultures reveal only beta-hemolytic streptococci (usually group A *Streptococcus* [GAS]), the oral antibiotic prescribed for impetigo and ecthyma should be effective for the treatment of both *S. aureus* and streptococcal infections.

The recommended oral antibiotic is flucloxacillin. However, if streptococci suspected in severe infection, then phenoxymethylpenicillin need to be added. If patient is penicillin-allergic, prescribe oral clarithromycin. The suggested duration of oral antibiotic treatment is for 7 days. Dosages of oral treatments (as per BNF Recommendations):

a. Flucloxacillin oral dosage

Adult and child above 10 years old, 250–500mg every 6 hours, at least 30 minutes before food.

Child:

1 month–2 years, 62.5–125mg every 6 hours, at least 30 minutes before food

2–10 years, 125–250mg every 6 hours, at least 30 minutes before food

b. Phenoxymethylpenicillin (Penicillin V)

Adult dose: 500mg every 6 hours, increased up to 1g every 6 hours if necessary;

Child up to 1 year: 62.5mg every 6 hours, increased up to 12.5mg/kg every 6 hours if necessary;

Child 1–6 years, 125mg every 6 hours, increased up to 12.5mg/kg every 6 hours if necessary;

Child 6–12 years, 250mg every 6 hours, increased up to 12.5mg/ kg every 6 hours if necessary

c. Clarithromycin (If penicillin-allergic) – oral dosage

Adult and Child over 12 years, 250mg every 12 hours, increased in severe infections to 500mg every 12 hours;

Child bodyweight under 8kg, 7.5mg/kg twice daily

Child bodyweight 8–11kg, 62.5mg twice daily;

Child bodyweight 12–19kg, 125mg twice daily;

Child bodyweight 20– 29kg, 187.5mg twice daily;

Child bodyweight 30–40kg, 250mg twice daily

11.3.3. Special cases — Certain scenarios warrant adjustments in the approach to treatment.

## 12. PROGNOSIS AND POSTINFECTIOUS COMPLICATIONS

12.1. Even without treatment, impetigo usually heals within 2-3 weeks. Randomized placebo arms in prospective clinical trials have noted a 13-52% spontaneous resolution rate. However, treatment produces a higher cure rate and reduces the

spread of infection to other parts of the body (via inoculation) or to other people. Scarring is unusual, but post inflammatory hyperpigmentation or hypopigmentation may occur. Untreated lesions of nonbullous impetigo may rarely progress to ecthyma, a deep dermal infection, after which subsequent scarring can occur.


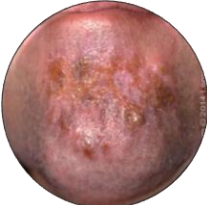



- 12.2. With appropriate treatment, lesions usually resolve after 7-10 days. If lesions persist beyond that point, cultures should be performed to look for resistant organisms. However, patients with eczema or an underlying parasitic infection may have a protracted course.
- 12.3. If the exfoliative toxins are absorbed into the bloodstream, staphylococcal scalded skin syndrome can result. This occurs more commonly in younger children, who have not developed antibodies against this toxin.
- 12.4. Poststreptococcal glomerulonephritis — Poststreptococcal glomerulonephritis is a potential complication of streptococcal impetigo that most often occurs within 1 to 2 weeks following infection. Common clinical findings include edema, hypertension, fever, and hematuria
- 12.5. Rheumatic fever — Recent evidence in Pacific communities where rheumatic fever is endemic demonstrate increasing evidence that skin-associated strains of group A streptococcal organisms being linked to cases of rheumatic fever




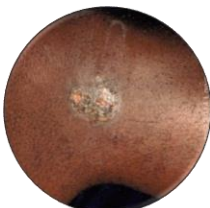
## REFERENCES

1. Baddour, L, [Internet]. Impetigo. UpToDate. [updated 2022; cited 2022 Jul 1]. Available from:  
<https://www.uptodate.com/contents/impetigo>
2. Joint Formulary Committee (2018) *British National Formulary*. Available  
at: <http://www.medicinescomplete.com> [Accessed 1 Jan. 2023].


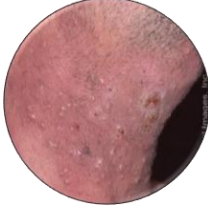
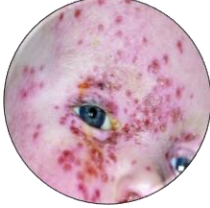

## APPENDICES

### APPENDIX 1 – TYPES OF IMPETIGO






Non-bullous Impetigo	
	<b>Picture A.</b> Perinasal erythema, erosions, and crusts in a child with nonbullous impetigo.
	<b>Picture B.</b> Gold-colored crusts on the chin of a patient with non-bullous impetigo.
	<b>Picture C.</b> "Honey-crusted" plaques on the face of a child with impetigo.
	<b>Picture D.</b> Impetigo vesiculopustules with crusting.
Bullous Impetigo	
	<b>Picture E.</b> Bullae, erosions, and crusts in a patient with bullous impetigo on the neck


	<p><b>Picture F.</b> Crusts at the sites of ruptured bullae in bullous impetigo.</p>
	<p><b>Picture G.</b> Multiple erosions with crust in a child with bullous impetigo.</p>
<p><b>Ecthyma</b></p>	
	<p><b>Picture H.</b> Multiple ulcers with adherent crusts.</p>
	<p><b>Picture I</b> Ulcer with adherent crust.</p>

## APPENDIX 2 – DIFFERENTIAL DIAGNOSIS

Non-bullous Impetigo	
	<p><b>Picture J.</b></p> <p>Discrete and confluent, red, scaly, weepy, crusted papules and plaques. A 25-year-old woman consulted a dermatologist for an acute, eczematous dermatitis on her head, neck, and shoulders. The eruption appeared 5 days after she had black hair dye applied to her hair at the hairdresser. Patch tests were positive for paraphenylenediamine. Paraphenylenediamine is a dark dye used in almost all permanent hair dyes and some semipermanent hair coloring. It is a potent allergen that triggers severe acute contact dermatitis in sensitized individuals.</p>
	<p><b>Picture K: Tinea Barbae</b></p> <p>Follicular pustules and crusted lesions in a patient with tinea barbae.</p>
	<p><b>Picture L: Eczema herpeticum</b></p> <p>Hemorrhagic crusts and vesicles due to herpes simplex virus infection are present on the face of this infant with underlying atopic dermatitis.</p>
Bullous Impetigo	
	<p><b>Picture M: Allergic contact dermatitis</b></p> <p>Vesicles and bullae developed on the volar forearm after application of perfume.</p>



	<p><b>Pictures N: Bullous arthropod (insect) bite</b> A bulla is present in the site of an insect bite.</p>
	<p><b>Pictures O: Chickenpox (varicella-zoster infection)</b> Numerous vesicles, some of which are hemorrhagic, on the face of a child with chickenpox.</p>
	<p><b>Picture P: Subcorneal pustular dermatosis (Sneddon-Wilkinson disease)</b> Multiple flaccid pustules and crusted plaques are present.</p>
<b>Ecthyma</b>	
	<p><b>Picture Q: Mycobacterium marinum infection</b> Ulcerative nodules on the arm.</p>
	<p><b>Picture R: Pyoderma gangrenosum</b> A purulent ulcer is present on the extremity.</p>

	<p><b>Picture S: Ecthyma gangrenosum</b> Retiform, purpuric lesions in a patient with ecthyma gangrenosum</p>
---	---

### APPENDIX 3 – AUTOIMMUNE MUCOCUTANEOUS BLISTERING DISEASES

Pemphigoid
<ul style="list-style-type: none"> <li>• Bullous pemphigoid</li> </ul>
<ul style="list-style-type: none"> <li>• Mucous membrane pemphigoid</li> </ul>
<ul style="list-style-type: none"> <li>• Pemphigoid gestationis</li> </ul>
<ul style="list-style-type: none"> <li>• Anti-laminin 332 pemphigoid (anti-epiligrin cicatricial pemphigoid)</li> </ul>
<ul style="list-style-type: none"> <li>• Anti-p200 pemphigoid (anti-laminin gamma-1 pemphigoid)</li> </ul>
<ul style="list-style-type: none"> <li>• Other pemphigoid variants</li> </ul>
Linear IgA* disease
<ul style="list-style-type: none"> <li>• Linear IgA bullous dermatosis</li> </ul>
<ul style="list-style-type: none"> <li>• Chronic bullous disease of childhood</li> </ul>
Pemphigus
<ul style="list-style-type: none"> <li>• Pemphigus vulgaris <ul style="list-style-type: none"> <li>○ Pemphigus vegetans</li> <li>○ Pemphigus herpetiformis</li> </ul> </li> </ul>
<ul style="list-style-type: none"> <li>• Pemphigus foliaceus <ul style="list-style-type: none"> <li>○ Pemphigus erythematosus</li> <li>○ Fogo selvagem</li> </ul> </li> </ul>
<ul style="list-style-type: none"> <li>• Paraneoplastic pemphigus</li> </ul>
<ul style="list-style-type: none"> <li>• IgA pemphigus <ul style="list-style-type: none"> <li>○ Subcorneal pustular dermatosis</li> <li>○ Intraepidermal neutrophilic IgA dermatosis</li> </ul> </li> </ul>
Bullous lupus erythematosus

**Dermatitis herpetiformis**

**Epidermolysis bullosa acquisita**

\*IgA: immunoglobulin A.

## APPENDIX 4 – VIRTUAL MANAGEMENT OF IMPETIGO ALGORITHM

